

Effect of treatment with carteolol and latanoprost in newly diagnosed primary open-angle glaucoma on peripapillary vessel density

Lestak Jan, Fus Martin, Pitrova Sarka

Background and Aim. In a previous follow-up of glaucoma patients taking carteolol or latanoprost, we found a greater progression of visual field changes with the prostaglandin than the betablocker. In the present study we compared the impact of carteolol and latanoprost on peripapillary vessel density in newly diagnosed primary open-angle glaucoma (POAG) patients.

Methods. The study consisted of two groups of POAG patients. There were 46 patient eyes treated with carteolol (Carteol LP 2%) in the first group and 52 eyes treated with latanoprost (Xalatan 0.005%) in the second. Intraocular pressure (IOP), vessel density (VD) and visual field were assessed in all patients. VD was measured peripapillary by optical coherence tomography angiography (OCTA) with the Avanti RTVue XR in eight segments: Inferior Temporal – IT (1); Temporal Inferior – TI (2); Temporal Superior – TS (3); Superior Temporal – ST (4); Superior Nasal – SN (5); Nasal Superior – NS (6); Nasal Inferior – NI (7) and Inferior Nasal – IN (8). The measurements were compared before and after three months of treatment. The visual field was examined with a fast threshold glaucoma program using a Medmont M 700 instrument from Medmont International Pty Ltd. and only when a diagnosis of POAG was done. The overall defect (OD) was assessed.

Results. Before treatment, there was no difference between groups in either OD or VD. After treatment, there was a decrease in IOP in both groups. In the carteolol-treated group, the mean decrease was 5.8 mmHg and in the latanoprost-treated eyes, the mean decrease was 7 mmHg. The difference was not statistically significant ($P=0.133$). After treatment with carteolol, there was a statistically significant increase in VD in segments 4, 5 and 6. After latanoprost treatment, VD was statistically significantly improved only in segment 5. A greater increase in VD values was found in eyes treated with carteolol than in eyes treated with latanoprost.

Conclusion. Carteolol had a better effect on vessel density than latanoprost.

Key words: primary open-angle glaucoma, peripapillary vessel density, treatment with carteolol and latanoprost.

Received: December 5, 2023; Accepted: February 26, 2024; Available online: March 21, 2024

<https://doi.org/10.5507/bp.2024.010>

© 2025 The Authors; <https://creativecommons.org/licenses/by/4.0/>

CTU in Prague, Faculty of Biomedical Engineering, 272 01 Kladno 2, Czech Republic

Corresponding author: Jan Lestak, e-mail: lestak@seznam.cz

INTRODUCTION

Glaucoma is a progressive disease in which early diagnosis is essential to preserve visual function. Due to the asymptomatic nature of glaucoma, early detection of the disease before its severe stages is challenging and the number of diagnosed glaucoma patients is lower than the number of undiagnosed^{1,2}. Lowering intraocular pressure (IOP) is generally considered standard treatment for glaucoma patients^{3,4}. Conventional first-line treatment of glaucoma usually starts with the use of a topical selective or non-selective beta-blocker or a topical prostaglandin analogue⁵⁻⁷. Prostaglandin analogues are recommended as the first-line treatment for primary open-angle glaucoma (POAG) because of their efficacy, limited systemic side effects and once-daily dosing⁸⁻¹⁰. Ocular carteolol is a nonselective beta-adrenoceptor antagonist with intrinsic sympathomimetic activity. Ocular carteolol effectively reduces intraocular pressure in patients with POAG. Like latanoprost, carteolol is applied once a day¹¹. Beta blockers cause a reduction in aqueous humour production¹².

Latanoprost is an ester analogue of prostaglandin F2alpha that reduces IOP by increasing uveoscleral outflow¹³.

In our previous study, we demonstrated changes in the vessel density peripapillary and in whole image with increasing IOP (ref.¹⁴). The most damaged vessels were located in segments 1, 4, 5, 6, 7 and 8 (ref.^{15,16}). In another study, we demonstrated a statistically significant improvement in VD of small and all vessels both peripapillary and whole image in eyes treated with carteolol. We found no statistically significant change with latanoprost¹⁷.

Because we compared the effect of these drugs on VD of all vessels and VD of small vessels peripapillary and whole image, we were interested in whether this difference in treatment would be seen in all or only some peripapillary segments.

MATERIALS AND METHODS

Patients who were newly diagnosed with primary open-angle glaucoma (POAG) and had not been treated

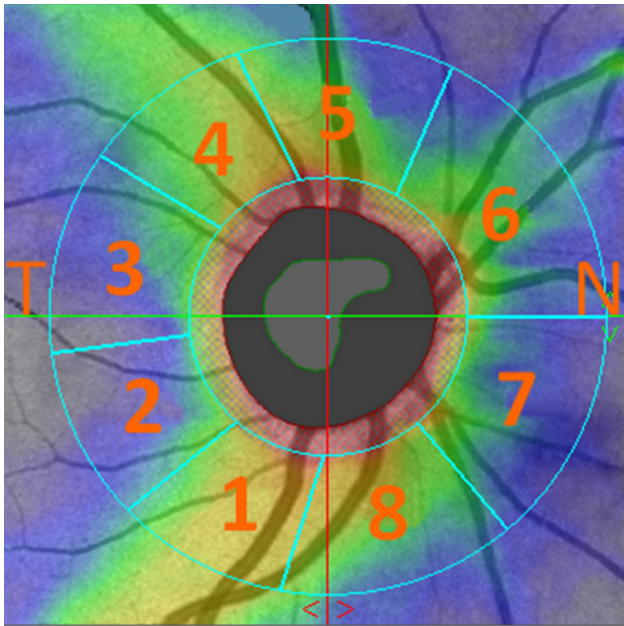


Fig. 1. Designation of each peripapillary segment in which RNFL and VD were evaluated.

Inferior Temporal – IT (1); Temporal Inferior – TI (2); Temporal Superior – TS (3); Superior Temporal – ST (4); Superior Nasal – SN (5); Nasal Superior – NS (6); Nasal Inferior – NI (7) and Inferior Nasal – IN (8).

with antiglaucomatous drugs were randomly divided into two groups with different medication. Inclusion criteria for the study: visual acuity 1.0 with possible correction $< \pm 3$ dioptres, no changes in visual fields in all subjects, no other ocular or neurological disease. No patient had normal tension glaucoma. The first group of 46 eyes (total of 12 females and 11 males, mean age $47.3 \text{ years} \pm 14.4$) were treated with carteolol (Carteol LP 2%). In this group were included only the patients without contraindications to beta-blocker use. The second group of 52 eyes (13 females

and 13 males, mean age 56.4 ± 13.6 years) were treated with latanoprost (Xalatan 0.005%).

The IOP was measured non-contact with an Ocular Response Analyser (ORA) from Reichert Technologies and the resulting IOP was averaged from the three measurements. VD was measured peripapillary by OCT (Avanti RTVue XR) in eight segments: Inferior Temporal – IT (1); Temporal Inferior – TI (2); Temporal Superior – TS (3); Superior Temporal – ST (4); Superior Nasal – SN (5); Nasal Superior – NS (6); Nasal Inferior – NI (7) and Inferior Nasal – IN (8) (Fig. 1).

The visual field was examined with a glaucoma program (fast threshold program of 50 degrees nasally and 22 degrees temporally) using a Medmont M 700 instrument from Medmont International Pty Ltd. To demonstrate that the glaucoma disease was approximately equally advanced, we assessed the overall defect (OD) of the visual field, only prior to treatment.

VD results in each segment were compared before and 3 months after treatment. The measured values were subjected to statistical processing. Since the two groups were different in age, statistical adjustment using multivariate regression models was necessary. The limit of statistical significance (P -value) was set at 0.05 for all statistical processing.

The Ethics Committee of the Ophthalmology Clinic of the JL FBE CTU at its meeting on 11 January 2021 discussed the request of the Head of the Ophthalmology Clinic of the JL FBE CTU about the intention to determine, in patients with different values of intraocular pressure, its influence on vessel densities, nerve fibre layer and visual field. The Commission found that this is not a clinical study, and the non-contact outpatient examinations performed will not affect or interfere with the health of the patient according to the Declaration of Helsinki of the World Medical Association (revised version 1 September 2000), and therefore this plan was not subject to approval by the Ethics Committee.

Table 1. The table shows the mean VD values (%) in each segment before treatment and their differences after three months of treatment.

Mean values of peripapillary vessel density (VD) [%]							<i>P</i> (difference between both treatment)
Segments	Carteolol treatment			Latanoprost treatment			
	before	after	difference	before	after	difference	
1-IT	55.70	57.55	1.85 (<i>P</i> =0.08)	54.70	55.95	1.25 (<i>P</i> =0.26)	0.65
2-TI	53.35	53.50	0.15 (<i>P</i> =0.84)	52.05	51.80	−0.25 (<i>P</i> =0.64)	0.31
3-TS	54.70	54.60	1.05 (<i>P</i> =0.12)	54.65	54.75	0.10 (<i>P</i> =0.92)	0.97
4-ST	54.75	55.35	1.95* (<i>P</i> =0.02)	53.85	54.95	1.10 (<i>P</i> =0.25)	0.55
5-SN	48.10	50.60	2.50* (<i>P</i> =0.01)	45.95	47.70	1.70* (<i>P</i> =0.02)	0.31
6-NS	48.35	49.55	1.25* (<i>P</i> =0.04)	46.15	47.20	1.05 (<i>P</i> =0.16)	0.15
7-NI	45.00	46.35	1.25 (<i>P</i> =0.12)	45.40	46.50	1.10 (<i>P</i> =0.17)	0.81
8-IN	48.40	49.45	1.05 (<i>P</i> =0.17)	46.07	48.25	1.55 (<i>P</i> =0.13)	0.47

1-IT (Inferior Temporal); 2-TI (Temporal Inferior); 3-TS (Temporal Superior); 4-ST (Superior Temporal); 5-SN (Superior Nasal); 6-NS (Nasal Superior); 7-NI (Nasal Inferior); 8-IN (Inferior Nasal).

Values marked with * indicate statistically significant P -values of VD change.

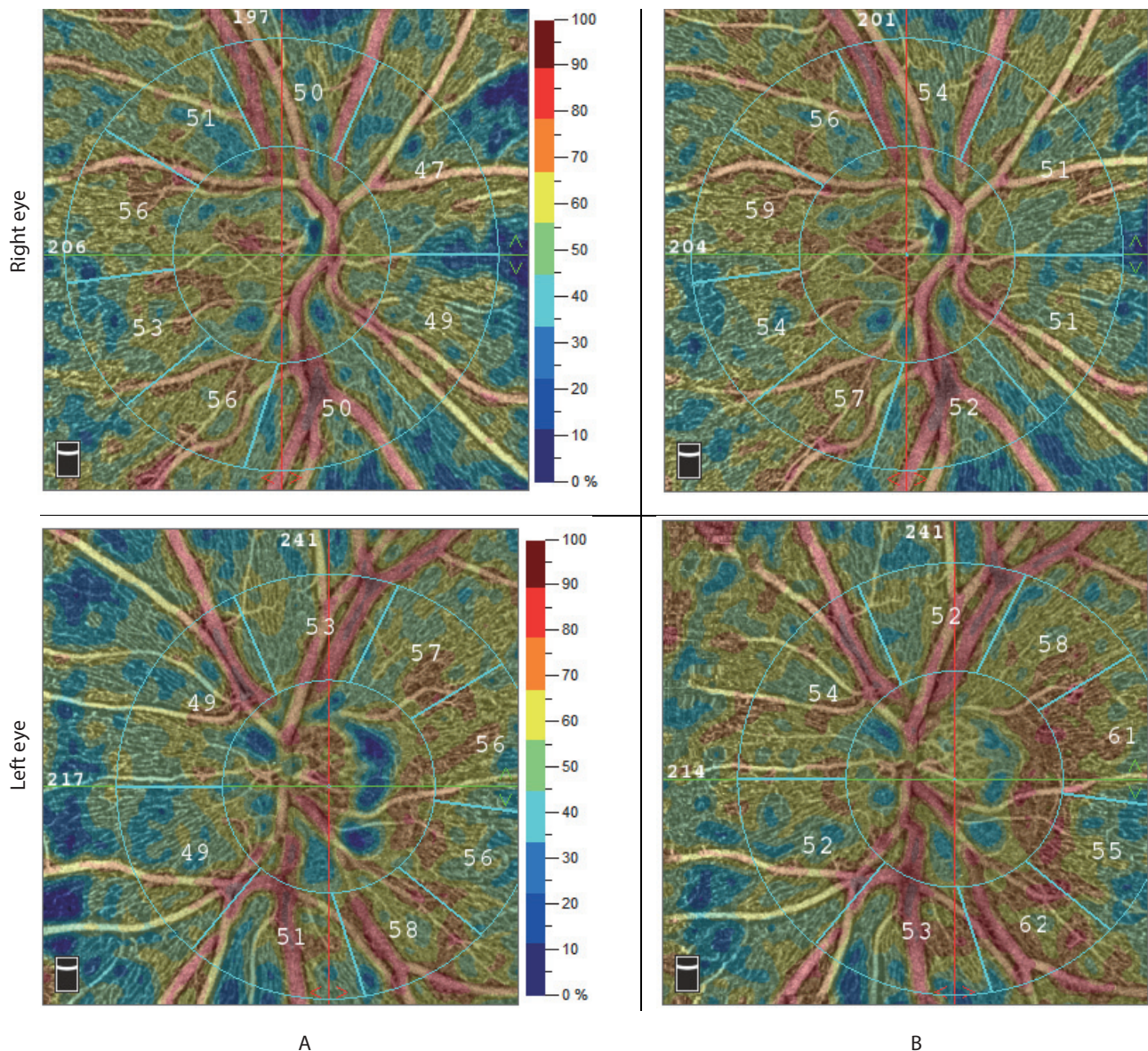


Fig. 2. Vessel density values in a patient born in 1974. A. before treatment; B. and after carteolol.

RESULTS

The mean VD values before treatment and the differences after three months are shown in the Table 1. OD of visual field before treatment was not statistically significant between the groups ($P=0.674$), confirming approximately the same equal changes of glaucoma progression in both groups. The carteolol group had a mean OD (2.09 ± 1.19) and the latanoprost group (2.197 ± 1.31).

Comparing the two groups, we also did not observe differences in VD in each segment before treatment. For carteolol, we found an increase in VD in all segments evaluated after treatment deployment. The statistically significant increase was in segments 4 ($r=1.95$, $P=0.02$), 5 ($r=2.50$, $P=0.01$) and 6 ($r=1.25$, $P=0.04$). For latanoprost, the increase was in segments 1, 3, 4, 5, 6, 7 and 8. There was a decrease in VD in segment 2. A statistically significant increase occurred for latanoprost only in segment 5 ($r=1.7$, $P=0.02$). The resulting differences in VD before

and after treatment were not statistically significant in individual segments when comparing the two drugs.

DISCUSSION

Accumulating evidence suggests that abnormalities in the retinal microcirculation contribute to the development of primary open-angle glaucoma^{18–20}. However, the precise role of vascular abnormalities in the pathogenesis of glaucoma remains poorly understood²¹.

In our previous study, where we investigated the relationship of VD peripapillary at different IOP values, we found no correlation for $IOP \leq 20$ mmHg. For $IOP > 20$ mmHg ($IOP < 22$ mmHg) the correlation reached intermediate values ($r=0.42–0.44$). For IOP values (>22 mmHg) it is also in medium correlation ($r=0.48–0.53$) and for values above 24 mmHg ($r=0.56$) although the correlation values increased it remains in the interval of medium values.

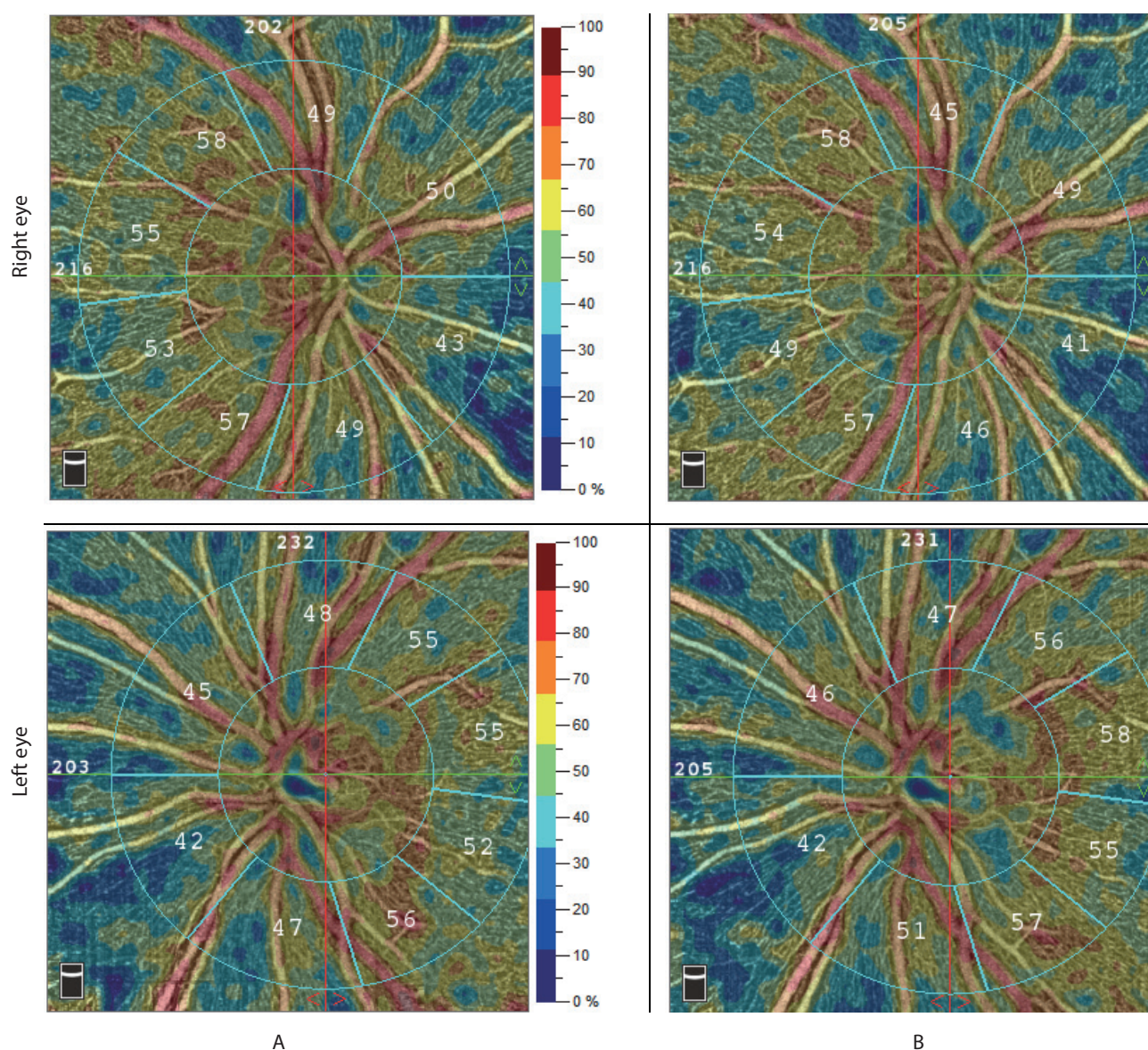


Fig. 3. Vessel density values in a patient born in 1969. A. before treatment; B. and after latanoprost.

This indicates that pathological IOP directly affects VD (ref.¹⁴). Vessel density has a large influence on the changes in the field of the POAG. Their loss results in an increase in the resistance index in the central retinal artery²². The loss of blood vessels may also be related to a decrease in total oxygen extraction from the retina, leading to structural and functional damage in glaucoma²³. Because beta-blockers and prostaglandins are among the main drugs in monotherapy for POAG (ref.²⁴), we enrolled just carteolol and latanoprost in our study.

A very interesting paper was presented by Diaz et al.²⁵, who measured after experimentally elevated IOP in rats, capillary density, capillary volume, length of capillary per unit volume, surface area of capillary per unit volume and mean capillary diameter in the prelaminar region (PLR), laminar region (LR), postlaminar region (PR) and optic nerve in four groups. The first was a control group where IOP was not elevated. The second after IOP increase, the third after IOP increase and timolol deployment and the

fourth after IOP increase and latanoprost deployment. The prelaminar region was at the level of the sclera.

The capillary density in the PLR was less than in the other regions of the optic nerve. No changes were found in this parameter in the PLR in the experimental group compared with the control group. Treatment with timolol or latanoprost failed to modify the values compared with the experimental group²⁵.

Chronic elevation of the IOP resulted in a significant reduction of the capillary volume in all the regions, 52% in the PLR, 78% in the LR, 88% in the PR, and 63% in the optic nerve compared with the control group ($P < 0.05$). After treatment with the two drugs, the capillary volume rose compared with the values seen in the experimental group, though without reaching the control group levels²⁵.

The length of capillary per unit volume fell significantly in the experimental group in all the regions studied: 73.5% in the PLR, 90% in the LR, 93.5% in the PR, and 76% in the optic nerve compared with the control group

($P < 0.05$). Treatment with timolol or latanoprost produced a significant increase in this parameter in the LR, in the PR, and in the optic nerve compared with the experimental group ($P < 0.05$). However, the differences in the LR and the optic nerve were not significant when compared with the control group²⁵.

The surface area of capillary per unit volume fell significantly after chronic elevation of the IOP in all the regions studied, especially in the PR (96%). Although topical treatment with timolol or latanoprost returned the surface area of capillary per unit volume values to those of the control group in the initial part of the optic nerve, it was onefold to twofold less in all the regions of the ONH after the two drugs²⁵.

The capillaries with the largest diameters were found in the PLR, in both the control group ($8.09 \pm 0.2 \mu\text{m}$) and the experimental group ($5.83 \pm 0.2 \mu\text{m}$). Compared with the control group, it was found a significant decrease in capillary diameter in all regions of the optic nerve in the experimental group ($P < 0.05$). After treatment, the mean capillary diameter increased significantly, except in the PLR (ref.²⁵).

When we look at these findings, we find that the greatest vascular changes occurred in the postlaminar region (PR). This is consistent with the available findings that in glaucoma, retinal ganglion cells (mostly magnocellular) are the first to die^{26–30}, then their axons located retrolaminarly and finally prelaminarly^{31,32}.

These findings are very important not only for the early diagnosis of glaucoma but also for the early treatment. For comparison with the results of our cohort, where we investigated vessel density in the prelaminar region.

No changes in capillary density were observed in the prelaminar region in the experiment. The values of capillary volume, length of capillary, surface area of capillary per unit volume and mean capillary diameter improved in the prelaminar region after treatment with latanoprost and timolol but did not reach the values of the control group²⁵.

Both groups of our cohort showed an improvement in vessel density (except for the temporal inferior segment – 2 in latanoprost). Statistically significant improvement between groups was achieved only in patients on carteolol.

In the experimental work of Diaz et al. both antiglaucomatous agents were applied one hour after the elevation of intraocular pressure and this treatment lasted for 90 days. We do not know the duration of glaucoma in our patients. Therefore, the decrease in vessel density in the prelaminar region in our study was also higher than in the work of Diaz et al.

In our previous work, where we evaluated peripapillary vessel density of all vessels, peripapillary vessel density of small vessels, vessel density of all vessels of the whole image and vessel density of small vessels of the whole image between the carteolol and latanoprost treated groups, we found a statistically significant difference only in the carteolol group¹⁷.

From the above experimental work of Diaz et al. capillary density values increased slightly after increasing the

intraocular pressure of the prelaminar vascular region. On the other hand, the values of length of capillary, surface area of capillary per unit volume and mean capillary diameter decreased after increasing IOP (ref.²⁵).

High intraocular pressure can affect the vascular system directly and also by increasing glutamate leakage throughout the visual pathway³³, which has an ischemic effect on the surrounding vascular system³⁴.

After prolonged duration of high IOP, damage occurs to the retinal ganglion cells, which are the largest (which are the fewest) in the periphery of the inferior temporal quadrant. Their fibres enter the optic nerve target in the inferior nasal segment – 8. Comparing this with the present work, we can conclude that there was an improvement in vessel density in this segment, but this improvement was not statistically significant. This is probably because in this segment the axons of just the magnocellular ganglion cells are the most atrophied, and in the periphery of the inferior temporal quadrant of the retina there are the fewest magnocellular cells that are nourished by these vessels. Parallel to this atrophy is a decrease in vessel density.

Other authors have also demonstrated a positive effect of medical IOP lowering on microvascular changes in glaucoma patients^{35–38}. Why latanoprost did not have the same effect on VD as carteolol in our study may be explained by the work of Zhou et al., who demonstrated that prostaglandins F2alpha can induce vasoconstriction³⁹. With carteolol, which also has an intrinsic sympathomimetic component, beta-adrenergic receptors on the small vessels of the optic nerve head are also blocked⁴⁰.

As mentioned in the introduction with increasing IOP, vessels localized in segments 1, 4, 5, 6, 7 and 8 were damaged^{15,16}. This means at the point where the optic nerve is entered by axons of mainly magnocellular retinal ganglion cells. Most of them are located in the upper nasal periphery, then in the lower nasal periphery. This is followed by the superior temporal and finally the inferior temporal retinal periphery⁴¹. As a result of our investigation in both groups, we found that both applied antiglaucomatous drugs had a significant effect on IOP reduction. However, we saw greater importance in the increase in VD observed with both drugs. For carteolol in all segments and for latanoprost in segments 1, 3, 4, 5, 6, 7 and 8. The increase in VD values was greater in eyes on carteolol. The highest increase was observed in segment 5. More importantly, however, we found a statistically significant change in carteolol in segments 4, 5 and 6. In latanoprost, only in segment 5. If we correlate this with RNFL loss, the biggest changes are in segments 5 and 8, as we have shown in other study¹⁶.

The European Glaucoma Society's latest 5th edition recommends prostaglandin analogues as the most effective drugs, and they are usually recommended as the first-choice treatment for HTG, also because of minimal systemic side effects⁴².

The results of our work indicate that both antiglaucomatous drugs had a significant effect on IOP reduction. We observed a greater decrease after latanoprost, although the difference between carteolol and latanoprost

was not statistically significant. However, we see greater importance in the increase in VD, which was significant for both drugs. After treatment with carteolol, there was a statistically significant increase in VD values in segments 4, 5 and 6. After latanoprost treatment, VD improved only in segment 5. A greater increase in VD values was observed in eyes treated with carteolol than in eyes with latanoprost.

We have not seen similar work in the available literature and believe that this will assist ophthalmologists in their decision making regarding the indication of antiglaucoma treatment.

CONCLUSION

Based on comparison of both antiglaucomatous drugs a better effect on vessel density of carteolol compared to latanoprost has been shown.

Author contributions: JL: conceptualization and design of the study, lead author of the manuscript; MF, SP: implementation of clinical investigations and outcome assessment, co-authorship of the manuscript.

Conflict of interest statement: The authors state that there are no conflicts of interest regarding the publication of this article.

Ethics approval and consent to participate: This study was conducted in accordance with the Declaration of Helsinki. All details, medical records, medical history or test results were used with the patient's written consent to participate and for publication. All data used were anonymized.

REFERENCES

- Burgoyne CF, Downs JC, Bellezza AJ, Suh JK, Hart RT. The optic nerve head as a biomechanical structure: a new paradigm for understanding the role of IOP-related stress and strain in the pathophysiology of glaucomatous optic nerve head damage. *Prog Retin Eye Res* 2005;24:39-73.
- Weinreb RN, Aung T, Medeiros FA. The pathophysiology and treatment of glaucoma: a review. *Jama* 2014;311:1901-11.
- Lichter PR, Musch DC, Gillespie BW, Guire KE, Janz NK, Wren PA, Mills RP; CIGTS Study Group. Interim clinical outcomes in the Collaborative Initial Glaucoma Treatment Study comparing initial treatment randomized to medications or surgery. *Ophthalmology* 2001;108:1943-53.
- Heijl A, Leske MC, Bengtsson B, Hyman L, Bengtsson B, Hussein M. Reduction of intraocular pressure and glaucoma progression: Results from the Early Manifest Glaucoma Trial. *Arch Ophthalmol* 2002;120:1268-79.
- Hoyng PF, van Beek LM. Pharmacological therapy for glaucoma: a review. *Drugs* 2000;59:411-34.
- Lee DA, Higginbotham EJ. Glaucoma and its treatment: a review. *Am J Health Syst Pharm* 2005;62:691-9.
- Kashiwagi K. Changes in trend of newly prescribed anti-glaucoma medications in recent nine years in a Japanese local community. *Open Ophthalmol J* 2010;28:7-11.
- Li T, Lindsley K, Rouse B, Hong H, Shi Q, Friedman DS, Wormald R, Dickersin K. Comparative Effectiveness of First-Line Medications for Primary Open-Angle Glaucoma: A Systematic Review and Network Meta-analysis. *Ophthalmology* 2016;123(1):129-40. doi: 10.1016/j.ophtha.2015.09.005
- Li F, Huang W, Zhang X. Efficacy and safety of different regimens for primary open-angle glaucoma or ocular hypertension: a systematic review and network meta-analysis. *Acta Ophthalmologica* 2018;96(3):e277–e284. doi: 10.1111/aos.13568
- Gedde SJ, Vinod K, Wright MM, Muir KW, Lind JT, Chen PP, Li T, Mansberger SL; American Academy of Ophthalmology Preferred Practice Pattern Glaucoma Panel. Primary Open-Angle Glaucoma Preferred Practice Pattern®. *Ophthalmology*. 2021;128(1):P71-P150. doi: 10.1016/j.ophtha.2020.10.022
- Matsuo M, Kuse Y, Takahashi K, Kuwahara K, Tanito M, Kaidzu S, Shimazawa M, Hara H, Ohira A. Carteolol hydrochloride reduces visible light-induced retinal damage in vivo and BSO/glutamate-induced oxidative stress in vitro. *J Pharmacol Sci* 2019;139(2):84-90. doi: 10.1016/j.jphs.2018.11.010
- Frishman WH, Fuksbrumer MS, Tannenbaum. Topical ophthalmic beta-adrenergic blockade for the treatment of glaucoma and ocular hypertension. *J Clin Pharmacol* 1994;34:795-803.
- Perry CM, McGavin JK, Culy CR, Ibbotson T. Latanoprost: an update of its use in glaucoma and ocular hypertension. *Drugs Aging* 2003;20:597-630.
- Kral J, Lestak J, Nutterova E. OCT angiography, RNFL and visual field at different values of intraocular pressure. *Biomed Rep* 2022;16:36. doi: 10.3892/br.2022.1519
- Lestak J, Fus M, Kral J. Axons of retinal ganglion cells on the optic nerve target at different values of intraocular pressure. *Clin Ophthalmol* 2022;16:3673-9.
- Lešták J, Füs M, Král J. Axons of retinal ganglion cells on the optic nerve disc following vessel density correction at different IOP values. *Exp Ther Med* 2023;25(6):261. doi: 10.3892/etm.2023.11960
- Nutterova E, Fus M, Bartosova L, Klimesova I, Lestak J. Comparison of the Effect on Vessel Density and RNFL between Carteolol and Latanoprost. *J Clin Med* 2022;11(14):4159. doi: 10.3390/jcm11144159
- Choi J, Kook MS. Systemic and ocular hemodynamic risk factors in glaucoma. *Biomed Res Int* 2015;2015:141905. doi: 10.1155/2015/141905
- Siesky B, Harris A, Vercellin ACV, Guidoboni G, Tsai JC. Ocular blood flow as it relates to race and disease on glaucoma. *Adv Ophthalmol Optom* 2021;6:245-62. doi: 10.1016/j.yaoo.2021.04.016
- Lestak J, Fus M, Rybar M, Benda A. OCTA and doppler ultrasound in primary open-angle glaucoma and normal-tension glaucoma. *Life* 2023;13(3):610. doi: 10.3390/life13030610
- Nakazawa T. Ocular blood flow and influencing factors for glaucoma. *Asia Pac J Ophthalmol (Phila)* 2016;5:38-44. doi: 10.1097/APO.0000000000000183
- Lešták J, Füs M, Benda A, Bartošová L, Marešová K. OCT Angiography and Doppler Ultrasound in Hypertensive Glaucoma. *Cesk Slov Oftalmol* 2021;77:130-3. doi: 10.31348/2021/15
- Garhöfer G, Bata AM, Popa-Cherecheanu A, Hommer A, Vass C, Resch H, Schmid D, Werkmeister RM, Schmetterer L. Retinal Oxygen Extraction in Patients with Primary Open-Angle Glaucoma. *Int J Mol Sci* 2022;23(17):10152. doi: 10.3390/ijms231710152
- Marquis RE, Whitson JT. Management of glaucoma: focus on pharmacological therapy. *Drugs Aging* 2005;22(1):1-21.
- Díaz F, Villena A, Vidal L, Moreno M, García-Campos J, Pérez de Vargas I. Experimental model of ocular hypertension in the rat: study of the optic nerve capillaries and action of hypotensive drugs. *Invest Ophthalmol Vis Sci* 2010;51:946-51.
- Glovinsky Y, Quigley HA, Dunkelberger GR. Retinal ganglion cell loss is size dependent in experimental glaucoma. *Invest Ophthalmol Vis Sci* 1991;32:484-91.
- Morgan JE, Uchida H, Caprioli J. Retinal ganglion cell death in experimental glaucoma. *Br J Ophthalmol* 2000;84:303-10.
- Naskar R, Wissing M, Thanos S. Detection of Early Neuron Degeneration and Accompanying Microglial Responses in the Retina of a Rat Model of Glaucoma. *Invest Ophthalmol Vis Sci* 2002;43:2962-8.
- Shou T, Liu J, Wang W, Zhou Y, Zhao K. Differential dendritic shrinkage of alpha and beta retinal ganglion cells in cats with chronic glaucoma. *Invest Ophthalmol Vis Sci* 2003;44:3005-10.
- Mukai R, Park DH, Okunuki Y, Hasegawa E, Klokman G, Kim CB, Krishnan A, Gregory-Ksander M, Husain D, Miller JW, Connor KM. Mouse model of ocular hypertension with retinal ganglion cell degeneration. *PLoS One* 2019;14(1):e0208713. doi: 10.1371/journal.pone.0208713

31. Quigley HA, Dunkelberger GR, Green WR. Chronic human glaucoma causing selectively greater loss of large optic nerve fibers. *Ophthalmology* 1988;95:357-63.
32. Soto I, Oglesby E, Buckingham BP, Son JL, Roberson ED, Steele MR, Inman DM, Vetter ML, Horner PJ, Marsh-Armstrong N. Retinal ganglion cells downregulate gene expression and lose their axons within the optic nerve head in a mouse glaucoma model. *J Neurosci* 2008;28(2):548-61. doi: 10.1523/JNEUROSCI.3714-07.2008
33. Vorwerk CK, Gorla MS, Dreyer EB. An experimental basis for implicating excitotoxicity in glaucomatous optic neuropathy. *Surv Ophthalmol* 1999;43(Suppl 1):142-50.
34. Tsuda Y, Nakahara T, Ueda K, Mori A, Sakamoto K, Ishii K. Effect of nafamostat on N-methyl-D-aspartate-induced retinal neuronal and capillary degeneration in rats. *Biol Pharm Bull* 2012;35:2209-13.
35. Tamaki Y, Araie M, Tomita K, Tomidokoro A, Nagahara M. Effects of topical adrenergic agents on tissue circulation in rabbit and human optic nerve head evaluated with laser speckle tissue circulation analyzer. *Surv Ophthalmol* 1997;42 Suppl 1:S52-63. doi: 10.1016/s0039-6257(97)80027-6
36. Holló G. Influence of Large Intraocular Pressure Reduction on Peripapillary OCT Vessel Density in Ocular Hypertensive and Glaucoma Eyes. *J Glaucoma* 2017;26:e7-e10.
37. Liu C, Umapathi RM, Atalay E, Schmetterer L, Husain R, Boey PY, Aung T, Nongpiur ME. The Effect of Medical Lowering of Intraocular Pressure on Peripapillary and Macular Blood Flow as Measured by Optical Coherence Tomography Angiography in Treatment-naïve Eyes. *J Glaucoma* 2021;30(6):465-72. doi: 10.1097/IJG.0000000000001828
38. Lin YH, Su WW, Huang SM, Chuang LH, Chen LC. Optical Coherence Tomography Angiography Vessel Density Changes in Normal-tension Glaucoma Treated with Carteolol, Brimonidine, or Dorzolamide. *J Glaucoma* 2021;30:690-6.
39. Zhou L, Zhan W, Wei X. Clinical pharmacology and pharmacogenetics of prostaglandin analogues in glaucoma. *Front Pharmacol* 2022;13:1015338. doi: 10.3389/fphar.2022.1015338
40. Feher J, Pescosolido N, Tranquilli Leali FM, Cavallotti C. Microvessels of the human optic nerve head: ultrastructural and radioreceptorial changes in eyes with increased IOP. *Can J Ophthalmol* 2005;40:492-8.
41. Curcio CA, Allen KA. Topography of ganglion cells in human retina. *J Comp Neurol* 1990;300:5-25. doi: 10.1002/cne.903000103
42. European Glaucoma Society Terminology and Guidelines for Glaucoma, 5th Edition. *Br J Ophthalmol* 2021;105(Suppl. 1):1-169. doi: 10.1136/bjophthalmol-2021-egsguidelines