

Compartment syndrome and regional anaesthesia: Critical review

Jozef Klucka^a, Petr Stourac^a, Alena Stouracova^b, Michal Masek^c, Martin Repko^d

Acute compartment syndrome (ACS) is a potential orthopaedic/traumatology emergency. Without prompt, precise diagnosis and immediate treatment with surgical decompressive fasciotomy it can lead to neurological dysfunction and disability. The role of regional anaesthesia (RA) in patients at risk for ACS/ and in those with developed ACS is controversial. The aim of this critical review was to answer the question, whether regional anaesthesia can delay the diagnosis. The authors use an evidence-based approach to discuss these high risk patients in considering RA as a method of choice for effective analgesia.

To the date of data collection, there was no single case report identified where RA alone led to delay in ACS diagnosis and surgical treatment. In four clinical cases, epidural analgesia can be associated with delayed ACS diagnosis. Frequent clinical evaluation and breakthrough pain despite a functional RA in combination with intracompartment pressure measurement remains the keystone of recommended management for patients at risk of ACS.

Key words: compartment syndrome, regional anaesthesia, peripheral nerve block/blockade

Received: December 16, 2016; Accepted: May 5, 2017; Available online: May 24, 2017

<https://doi.org/10.5507/bp.2017.025>

^aDepartment of Paediatric Anaesthesiology and Intensive Care Medicine, Faculty of Medicine, Masaryk University and University Hospital Brno, Jihlavská 20, 625 00 Brno, Czech Republic

^bDepartment of Radiology, Faculty of Medicine, Masaryk University and University Hospital Brno, Jihlavská 20, 625 00 Brno, Czech Republic

^cDepartment of Traumatic Surgery, Faculty of Medicine, Masaryk University and University Hospital Brno, Jihlavská 20, 625 00 Brno, Czech Republic

^dDepartment of Orthopaedic Surgery, Faculty of Medicine, Masaryk University and University Hospital Brno, Jihlavská 20, 625 00 Brno, Czech Republic

Corresponding author: Petr Stourac, e-mail: petr.stourac@gmail.com

INTRODUCTION

Compartment syndrome (CS) is a clinical condition where increase in pressure within a closed compartment leads to perfusion abnormalities, ischemia and neurological damage. CS is considered a real orthopaedic/traumatology emergency¹. There are several pathophysiologic theories for describing this syndrome including the arteriovenous gradient theory and the ischemia-reperfusion syndrome². However, whether there is a extraluminal or intraluminal pressure increase, the main principle remains the same - the pressure increase leads to capillary blood flow restriction, decrease in tissue pO₂ and consequently to tissue hypoxia and ischaemia². The pressure elevation in the compartment can arise from the inflammatory response, oedema, haemorrhage or ischaemia reperfusion syndrome, arterial pathology and also from external compression from casts, tight bandages, dressings or burns³⁻⁵. CS has been diagnosed in a variety of anatomical compartments including leg, gluteal region, thigh, tibia, foot, arm, forearm, hand and abdomen⁴. Fractures of the long bones, predominantly tibia (diaphysis) are the cause of approximately 75% of ACS and the risk is even higher in the case of comminuted fractures⁶⁻⁷. Soft tissue injuries without fracture represent the cause of around 20% of ACS. The reported incidence of ACS is 3.1 per 100 000, and ten times higher in men⁸. The incidence in the paediatric population is even lower although due to physiologic higher

intracompartment pressure (13-16 mmHg vs. 0-10 mmHg) children are at greater risk of ACS (ref.⁹). Identified risk factors for ACS are: male gender, young age <35 years, open fracture, intramedullary nailing, anticoagulation therapy, high-energy and penetrating trauma, vascular injuries, tourniquet use, haemophilia and complications of intravenous and intraosseous infusions^{8,10-19}.

Prompt diagnosis of ACS is crucial and significantly lowers the morbidity. Clinical signs of ACS are known as 5/6P: pain out of proportion to injury and pain with acute stretch, pallor, pressure, paraesthesia, paralysis and pulselessness²⁰⁻²¹. Pulselessness is not frequent, it is considered as a late sign²² and is associated with bad prognosis²²⁻²⁴. Clinical findings for ACS are however unreliable and can lead to delay in treatment^{5,25} because ACS can also present without any pain (in up to 10% of patients with ACS) (ref.^{3,26}). The most reliable method for diagnosis seems to be frequent assessment of a patient's clinical condition combined with intracompartment pressure monitoring in high risk patients. Intracompartment pressure monitoring (ICP) is considered as a "gold standard" for ACS diagnosis and for decompressive fasciotomy indication^{5,14,16,24,27}. The normal intracompartment pressure is in between 0-8 mmHg or below 10-12 mmHg according to different data^{9,28-30}. Pain is common with the ICP pressure over 20 mmHg and pressure over 30 mmHg is considered to be indication for emergency fasciotomy^{8,10,27,31,32}, but the precise value varies in the literature between 30-45 mmHg³³⁻³⁴.

Other authors recommend the Δ pressure - perfusion pressure (Δ pressure = diastolic blood pressure - intracompartmental pressure) with a threshold of 30mmHg³⁵. Δ pressure has been reported as more sensitive than the absolute measured pressure and can lead to minimizing the risk of unnecessary fasciotomy³⁶⁻³⁷. Data are consistent for the urgent indication for fasciotomy in ACS and it appears that performing the fasciotomy within 6 hours after diagnosis (after onset of ACS) is associated with good outcome - 88% good outcome, 3.2% amputation rate compared to fasciotomy after 12 hours - good outcome only in 15% of patients with 14% amputation rate³⁸⁻³⁹. The fasciotomy timing is not based on the robust evidence-based data (EBM) and neurological deficit can be diagnosed in cases with rapidly performed fasciotomy (in 2 h). Hence, this seems to indicate fasciotomy as quickly as possible after confirmation of the ACS (ref.⁴⁰).

Decompression with surgical fasciotomy is considered a gold standard for therapy CS. The timing of fasciotomy is important and the best functional results without neurologic consequences are achieved when fasciotomy is performed within six hours from onset of CS (ref.²⁷). Regional anaesthesia (RA) is considered as a possible risk factor that can delay the diagnosis of acute CS (ACS) (ref.⁴¹⁻⁴³). Data are however derived only from case reports and case series and currently there is no uniform opinion in the literature or in clinical practice on the role of RA in patients in ACS or at risk of ACS formation. Therefore, we decided to conduct the review of literature to answer whether the regional anaesthesia can lead to delay in diagnosis and treatment of ACS.

RESULTS

In the initial results we identified 294 citations, 88 were related to the topic: compartment syndrome and regional anaesthesia in the reviewed time period. After exclusion of duplicates (n=56), articles not in English (n=3) and articles with no available abstract or full-text online (n=7) a total of 22 full-text articles were included in the final analysis: case reports (n=15), review of literature (n=5), clinical trial (n=1), systematic review (n=1). Search diagram is showed in Figure 1.

No randomized controlled study dedicated to the topic was found. The currently available published data are of low-EBM (evidence-based medicine) quality (case reports, case series, retrospective data) with the high risk of bias and that is the main limitation of this review.

In selected 15 case reports were 20 published clinical cases - Table 1. The case reports were divided into 3 sections according to type of anaesthesia: regional anaesthesia, intravenous regional anaesthesia and epidural or subarachnoid/spinal anaesthesia and analgesia. No single case (0/8) in regional anaesthesia subgroup was found to be related to delay in acute compartment syndrome (ACS) diagnosis. In 7 cases, breakthrough pain appeared despite functional regional analgesia and in 1 case there was swelling, blisters and passive extension excessive pain.

In the intravenous regional anaesthesia subgroup only

two case reports were included in the review. In both, pain immediately (0-30 minutes after surgery) led to ACS diagnosis.

10 case reports were included in the epidural/spinal anaesthesia and analgesia subgroup. In 6 cases anaesthesia/analgesia did not lead to delay in ACS, because clinical signs of compartment syndrome were present despite functional blockade or the ACS appeared after a prolonged interval after epidural analgesia discontinuation. In 2 published cases Tang et al.⁴⁴ and Somayaji et al.⁴⁵ the epidural analgesia could have led to delay in ACS diagnosis however, in the first case there were some clinical signs of ACS - swollen calf, diminished capillary return. In the second case, dense block were persistent 24 h after epidural induction. In both cases the delayed diagnosis led to permanent neurological deficit. In Kumar et al.⁴⁶ case 3 and case 4, the pain appeared 4 h after epidural analgesia discontinuation. Epidural analgesia led to the delay. However there were clinical signs of ACS: erythema, tense and tender area and swelling in both patients. After urgent fasciotomy both patients fully recovered with no neurological deficit.

The only one included clinical trial (Maletis et al.⁴⁷), compared the frequency of ACS in patients undergoing closed reduction of closed lower leg shaft fractures under general or intravenous regional anaesthesia. General anaesthesia had favourable effect with only 13% vs. 27% rate of ACS diagnosis. The reason for the higher incidence may be, according to the authors, explained by the thigh tourniquet use.

In the recently published systematic review by Driscoll et al.⁴⁸, the authors compared regional anaesthesia and the patient-controlled analgesia (PCA) in patients with compartment syndrome. Although they used different search methods and a different approach for considering the effect of anaesthesia and analgesia on the delay in ACS diagnosis, in 6/8 (75%) patients in the PCA group ACS was diagnosed with a delay compared to the RA group where delay in diagnosis was detected in 19/29 (65%) case reports (Table 1). When comparing the possible influence of RA on delay in time (considering the evolution in regional anaesthesia - lower dosing, lower concentrations, ultrasound guidance), the more recently published data (after 2009) claimed that in 75% cases, no association between RA and delay in ACS was detected⁴⁸.

DISCUSSION

Our results showed no relationship between functional regional anaesthesia and delay in ACS diagnosis. Intravenous regional anaesthesia can be associated with risk of ACS development, because the prolong and excessive cuff pressure can lead to ACS formation. However, currently, intravenous regional anaesthesia is used only occasionally. Regional continuous analgesia is considered superior to opioid-based analgesia and can lead to reduction of in-hospital stay and chronic pain incidence⁴⁹. Regional anaesthesia (RA) in patients with ACS or in patients at risk is controversial, however we found no

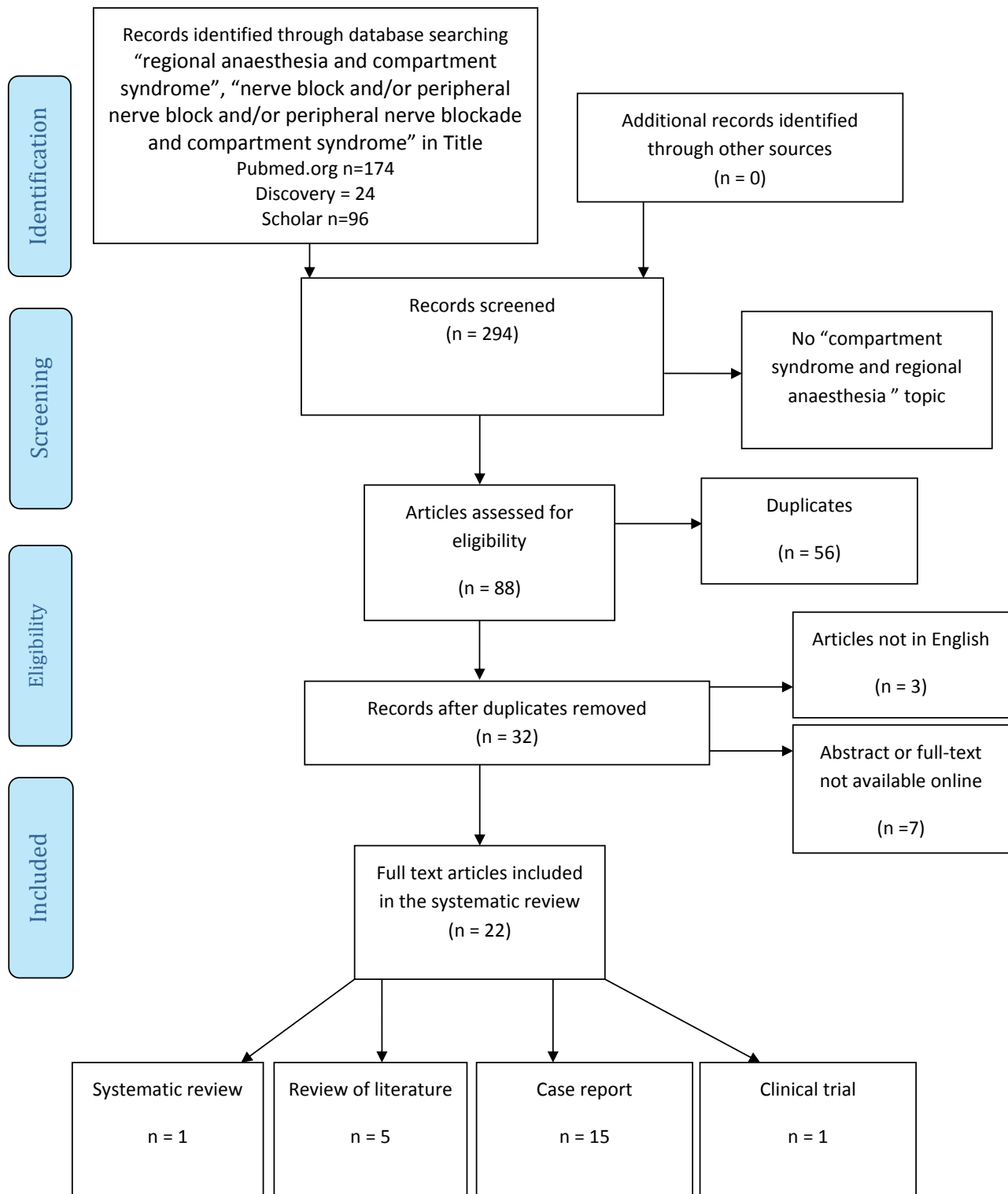


Fig. 1. Data search diagram.

published case report confirming that regional anaesthesia was the primary cause of the delay in ACS (ref.⁵⁰⁻⁵¹), Aguirre et al.³⁸ analysed 5 published case reports blaming RA for delay in ACS diagnosis, however in all cases the breakthrough pain was missed. From an ethical and pathophysiological point of view the patient's pain should be treated and there are several published case reports on opioid-based pain management has led to delay in ACS

diagnostics⁵⁰⁻⁵¹. For this reason, the analgesic method per se cannot be considered as the reason for delay in diagnostics^{50,52}. Cometa et al.⁵³ and Walker et al.⁵⁴ reported that despite functional continuous regional blockade, ischaemic pain was unaffected and patients can present with breakthrough pain.

It seems that compartment syndrome can be safely detected despite functional regional blockade⁵⁵ and pa-

Table 1. List of case reports.

| Author | Clinical condition, type of surgery | Type of anaesthesia | Symptoms of Acute compartment syndrome (ACS) | Clinical management | Time of ACS diagnosis | Intracompartment pressure values | Fasciotomy | Did regional anaesthesia/analgesia mask the symptoms of ACS | Neurologic recovery | Authors comments | Ref. |
|---|--|---|---|---|------------------------------------|----------------------------------|------------------------|--|---------------------|---|------|
| Regional anaesthesia / analgesia | | | | | | | | | | | |
| Uzel et al. | closed femoral fracture internal fixation | single-injection femoral block + general anaesthesia | 1st day after surgery - disproportionate pain | Intracompartment pressure monitoring, ACS diagnosed, fasciotomy performed | 1st postoperative day | compartment pressure 54 mmHg | YES | NO | Full recovery | 3 h and 40 min after surgery breakthrough pain (despite functional regional blockade) - subcutaneous morphine | 58 |
| Cometa et al. | distal femur and proximal tibia osteotomy with external fixation | continuous femoral and sciatic nerve blocks + general anaesthesia | 2nd postoperative day, severe pain despite effective blocks and oral opioids | ACS diagnosed, fasciotomy performed | 2nd postoperative day | over 30 mm Hg | YES | NO - breakthrough pain despite functional regional analgesia | Full recovery | breakthrough pain despite functional regional analgesia | 53 |
| Kucera, et al. Case 1 | right lateral ankle ligament reconstruction | single-injection femoral and sciatic nerve blocks | 90 min after the cast dressing - severe pain despite persistent complete sensory and motor blockade | cast removal and reapplied | 90 min after surgery | NOT measured | NO | NO - breakthrough pain despite functional regional analgesia | Full recovery | breakthrough pain despite functional regional analgesia | 57 |
| Aguirre et al. | complex distal humerus fracture | infraclavicular catheter + general anaesthesia, patient-controlled regional analgesia postoperatively | severe forearm pain 14 hours after surgery despite functional regional analgesia | Intracompartment pressure monitoring, ACS diagnosed, fasciotomy performed | 14 h after surgery | 40 mmHg | YES | NO - breakthrough pain despite functional regional analgesia | Full recovery | breakthrough pain despite functional regional analgesia | 38 |
| Rauf et al. | open reduction and internal fixation of the radius | supraclavicular brachial plexus block + general anaesthesia | disproportionately intense pain despite an otherwise fully functioning sensory and motor block, swollen, tender, loss of radial pulse | revision surgery - haematoma evacuation | after surgery - time not specified | NOT measured | YES - revision surgery | NO - breakthrough pain despite functional regional blockade | Full recovery | clinical signs of ACS despite functional regional blockade | 59 |
| L. Sermeus et al. | forearm osteochondroma resection | Infraclavicular block + general anaesthesia | Breakthrough pain despite functional regional block. Motor function and sensitive deficit, swollen fingers | forearm cast removal - pain disappeared while motor function and sensation recovered. | In the night - time not specified | NOT measured | NO | NO - breakthrough pain despite functional block | Full recovery | ACS diagnosed - loss of sensation, motor function deficit and breakthrough pain | 4 |
| Munk-Andersen et al. | open tibial shaft fracture | single-shot distal sciatic nerve preoperatively and postoperatively, 1st postoperative day - distal sciatic nerve catheter was inserted | calf muscles were tense and sore, patient suddenly experienced severe pain in the lower leg | ACS diagnosed and fasciotomy performed | 1st postoperative day | NOT measured | YES | NO - breakthrough pain despite functional regional analgesia | Full recovery | breakthrough pain despite functional regional analgesia | 60 |

Table 1. Continued

| Author | Clinical condition, type of surgery | Type of anaesthesia | Symptoms of Acute compartment syndrome (ACS) | Clinical management | Time of ACS diagnosis | Intracompartment pressure values | Fasciotomy | Did regional anaesthesia/analgesia mask the symptoms of ACS | Neurologic recovery | Authors comments | Ref. |
|---|-------------------------------------|---|---|---|---------------------------|--|----------------------|---|------------------------------|---|------|
| Ganeshan et al. | internal fixation radius | axillary nerve block, the patient was discharged the same day, as he was pain free and comfortable | 24 hours after surgery loss of sensation in the fingers; multiple swellings over the forearm and hand, oedematous, elbow with multiple haemorrhagic blisters, no active movements of the fingers and wrist, passive movements were painful and limited, passive extension of the fingers caused severe pain | ACS of the forearm diagnosed and fasciotomy was performed | 24 h after surgery | 46 and 50 mm Hg in the anterior compartment and a reading of 22 mm Hg in the posterior compartment of the forearm were noted | YES | NO – clinical signs of compartment – loss of sensation, no active movement, severe pain with passive movement | Permanent neurologic deficit | Clinical signs of ACS were present despite functional regional blockade | 61 |
| Intravenous regional anaesthesia | | | | | | | | | | | |
| Ananthanarayan et al. Case 1 | left-hand Dupuytren's contracture | iv regional anaesthesia with 360 mg lidocaine and sedation, tourniquet time was 107 min at a pressure of 260 mmHg | increased forearm muscle tension, hand anaesthesia, pallor, and limited motor function developed | ACS diagnosed and fasciotomy was performed | immediately after surgery | NOT measured | Several fasciotomies | NO – pain immediately after end of the operation | Permanent deficit | ACS diagnosed immediately after surgery, intravenous regional anaesthesia complication | 62 |
| Ananthanarayan et al. Case 2 | Dupuytren fasciotomy | iv regional anaesthesia, tourniquet time was 64 min at a pressure of 250 mmHg | pain and swelling of the forearm 30 min after operation | ACS diagnosed and fasciotomy was performed | 30 min after surgery | NOT measured | YES | NO – pain 30 minutes after end of the operation | Full recovery | ACS diagnosed 30 min after surgery, intravenous regional anaesthesia complication | 62 |
| Epidural/spinal anaesthesia and analgesia | | | | | | | | | | | |
| Tang et al. | total knee arthroplasty | epidural anaesthesia/analgesia postoperatively | swollen calf immediately after surgery, 2nd postoperative day – diminished capillary return | intracompartment pressure monitoring, ACS diagnosed, Fasciotomy performed | 2nd postoperative day | The pressure of the anterior, peroneal, superficial, and deep posterior compartments was 65, 75, 75, and 80 mm Hg | YES | YES | Permanent neurologic deficit | clinical sign of ACS – diminished capillary return, authors describe full anaesthesia below pelvis with epidural analgesia on the 2nd day | 44 |
| Somavajji et al. | hip arthroplasty | epidural anaesthesia/analgesia + general anaesthesia | dense block, tachycardia and a temperature of 38.5 °C, severe pain after epidural analgesia stopping, discomfort in both buttocks | epidural infusion stop, ASC diagnosed, Fasciotomy performed | 36 h postoperatively | NOT measured | YES | YES | Permanent deficit | dense block persistent 24 h after epidural induction need further clinical investigation | 45 |

Table 1. Continued

| Author | Clinical condition, type of surgery | Type of anaesthesia | Symptoms of Acute compartment syndrome (ACS) | Clinical management | Time of ACS diagnosis | Intracompartment pressure values | Fasciotomy | Did regional anaesthesia/analgesia mask the symptoms of ACS | Neurologic recovery | Authors comments | Ref. |
|-----------------------|--|--|---|---|--|---------------------------------------|--|--|--------------------------------------|--|------|
| Kucera, et al. Case 2 | necrotic lesions of 4th and 5th digits | continuous cervical paravertebral block | despite dense sensory and motor blockade, she still reported excruciating pain | intravenous opioids insufficient - brachial to palmar arch bypass failure, amputation of the 4th and 5th finger | immediately after surgery | NOT measured | NO - vascular bypass surgery | NO - breakthrough pain despite functional regional analgesia | amputation of the 4th and 5th finger | breakthrough pain despite functional regional analgesia | 57 |
| Streker et al. | tibial soft tissue defect - fibular transfer | epidural anaesthesia / analgesia | swollen leg 4 days after surgery | epidural removal | dull pain after epidural removal, persistent pain for 3 days after epidural removal, dysesthesia | NOT measured | revision | NO - pain appeared after epidural removal | NOT clear | late ACS diagnosis not masked by epidural analgesia | 63 |
| Pinheiro et al. | total knee arthroplasty | subarachnoid block + epidural catheter insertion | hyposthesia and mobility limitations 1st postoperative day | epidural infusion stopped, parenteral analgesia | 2nd day - neurological deficit | NOT measured | YES | NO - at the time of ACS diagnosis | Full recovery | ACS diagnosed in patient receiving parenteral opioids | 64 |
| O. Ross et al. | 6-year-old child, midshaft tibial fracture | caudal epidural injection + general anaesthesia | 7 h after surgery when she experienced ever increasing pain despite intravenous opioids | ACS diagnosed a fasciotomy performed | 7 h after surgery | YES (values not included in the text) | YES - several hours after breakthrough pain | NO - despite functional epidural analgesia the breakthrough appeared | Full recovery | breakthrough pain appeared despite functional epidural analgesia, the pain was treated with i.v. opioids | 65 |
| Kumar et al. Case 1 | total knee arthroplasty | epidural anaesthesia, the epidural infusion was discontinued after 20 h introduced at the L4/5 level | pain in the left buttock 28 h after discontinuation of the epidural infusion, tense, tender swelling no abnormal neurological findings. | acute gluteal compartment diagnosed and fasciotomy was performed | 48 h after initial surgery (28 h after epidural infusion stopping) | Not measured | YES - 48 h after initial surgery (28 h after epidural infusion stopping) | NO - pain appeared 28 h after epidural infusion stopping | Full recovery | pain appeared 28 h after epidural infusion stopping | 46 |
| Kumar et al. Case 2 | total hip arthroplasty | epidural anaesthesia at the L4/5 level, epidural infusion for 28 h | severe right buttock pain 16 h after discontinuation of the epidural infusion, firm, tense, tender swelling with erythema | acute gluteal compartment diagnosed and fasciotomy was performed | appeared 16 h after epidural infusion stopping | Not measured | YES - 44 h after the initial operation | NO - pain appeared 16 h after epidural infusion stopping | Full recovery | pain appeared 16 h after epidural infusion stopping | 46 |

Table 1. Continued

| Author | Clinical condition, type of surgery | Type of anaesthesia | Symptoms of Acute compartment syndrome (ACS) | Clinical management | Time of ACS diagnosis | Intracompartment pressure values | Fasciotomy | Did regional anaesthesia/analgesia mask the symptoms of ACS | Neurologic recovery | Authors comments | Ref. |
|---------------------|-------------------------------------|--|---|--|--|----------------------------------|--|---|---------------------|---|------|
| Kumar et al. Case 3 | right hip arthroplasty | epidural anaesthesia at the L3/4, epidural infusion for 19 h | left buttock pain 4 h after discontinuation of the epidural infusion, erythematous, tense, and tender area over the left buttock and pain on passive flexion at the hip. | acute gluteal compartment diagnosed and fasciotomy was performed | 4 h after epidural infusion stopping | not measured | YES - 28 h after the initial operation | YES - pain appeared 4 h after epidural infusion stopping | Full recovery | other clinical signs of ACS were present - erythema, tense and tender area | 46 |
| Kumar et al. Case 4 | total knee arthroplasty | epidural anaesthesia at the L1/2, epidural for 43 h | right foot drop - 4 h after the epidural infusion stopping, loss of sensation - sciatic nerve, no active movements at the ankle, swelling and tenderness over the right buttock | acute gluteal compartment | 4 h after the epidural infusion stopping | not measured | YES - timing is not clear | YES - pain appeared 4 h after epidural infusion stopping | Full recovery | tourniquet was applied for 1 h and 50 ml, other clinical signs of ACS were present - swelling and tenderness over the right buttock | 46 |

tients present with the classical signs of ACS (ref.²³). The French Society of Anaesthesia does not consider the risk of ACS as a contraindication for regional anaesthesia⁵⁶ and because there is evidence that regional blockade can increase the blood flow through the partial sympathetic blockade without blocking the warning signs of ACS, the implementation of regional anaesthesia also in patients in the risk of ACS should be encouraged.

For minimizing the risk of delay ultrasound guidance for regional blockade and the catheter insertion, which can lead to lowering the dose of local anaesthetics are strongly recommended. Low concentrations of local anaesthetics can facilitate the motor function of the limb and allow breakthrough pain detection^{3,23,38,57}.

Several cases (Kumar et al.⁴⁶) reported, that epidural analgesia can lead to delay in ACS diagnosis, however the ACS is a complex syndrome and can present also without pain. In the majority of these cases there were other clinical signs of ACS presentation. These high-risk patients should be more frequently evaluated and intracompartment pressure measurement should be used. Frequent clinical re-evaluation of the patient's condition, increasing demands for analgesia and presence or reoccurrence of the breakthrough pain despite the functional RA should be incorporated in to management of the patient in the risk of ACS.

One interesting observation can be found in Driscoll et al.⁴⁸, that most of the articles pinpointing the delay in ACS diagnosis on RA were published in surgical/orthopaedic journals and most of the articles defending RA were published in anaesthesiology journals, which corresponds daily clinical practice.

Currently the EBM data considering the ideal analgesic method in patients with the risk of ACS is insufficient. Every single analgesic method can be associated with the delay in ACS diagnosis if pain is the sole diagnostic criteria. As opioids (PCA) can lead to even higher incidence of delay compared to regional anaesthesia⁴⁸ and it is highly unethical not to treat the pain, the complex management of the whole patient at risk of ACS appears to be more important than the analgesic method alone.

Summary of evidence

We found no prospective RCT dedicated to this theme and the reviewed data can be considered as low-EBM quality (case reports, case series). Currently clinical practice is based on several reported cases and the theme is considered controversial.

Limitations

The main limitation is sparse data of low quality, search strategy limited by 3 databases (PubMed, Scholar, google, EBSCO - Discovery) and inclusion only the articles in the English language.

CONCLUSION

Results of the review didn't show, that RA can be associated with higher risk in delay ACS diagnosis compared

to other analgesic methods (intravenous opioid analgesia, epidural analgesia, PCA) and the cornerstone of diagnosis and treatment has to be the complex management including the intracompartment pressure monitoring in selected high-risk patient. Pain alone must not be considered as a single diagnostic sign of compartment syndrome.

However it must be noted that the evidence is sparse and no clear guideline is currently available. There is an urgent need for discussion between orthopaedic/traumatology and anaesthesiology communities with the aim of establishing clear recommendation how to proceed in this clinical scenario.

Search strategy and selection criteria

This article followed the PRISMA Statement (www.prisma-statement.org) for meta-analysis and reviews.

We searched the following databases: Scholar Google (<https://scholar.google.com>), PubMed (<http://www.ncbi.nlm.nih.gov/pubmed/>), Discovery - EBSCO discovery service for keywords: regional, anaesthesia and compartment syndrome, nerve block or peripheral nerve block or peripheral nerve blockade and compartment syndrome located in the title or in the abstract.

We searched for data published between 1980 and 12/2016. All full-text articles in English related to the topic regional anaesthesia and compartment syndrome were included. Inclusion criteria were: articles found by selected search strategy (keywords, published between 1980-2016, selected databases), written in English language, full-text available and dedicated to the topic, compartment syndrome. Exclusion criteria were: abdominal compartment syndrome, articles not related to the topic CS and regional anaesthesia.

Acknowledgment: The article was published with the support by MZ ČR RVO (FNBr, 65269705) Czech Republic.

Author contributions: JK, PS, AS, MM, MR designed the review, searched the articles in databases, interpreted findings, wrote the article and approved final text of the manuscript.

Conflict of interest statement: The authors state that there are no conflicts of interest regarding the publication of this article.

REFERENCES

1. Tzioupis C, Cox G, Giannoudis PV. Acute compartment syndrome of the lower extremity: an update. *Orthopaed Trauma* 2009;23(6):433-40.
2. Janzing H. Epidemiology, etiology, pathophysiology and diagnosis of the acute compartment syndrome of the extremity. *Eur J Trauma Emerg Surg* 2007;33(6):576-83.
3. Walker BJ, Noonan KJ, Bosenberg AT. Evolving compartment syndrome not masked by a continuous peripheral nerve block: evidence-based case management. *Reg Anesth Pain Med* 2012;37(4):393-7.
4. Sermeus L, Boeckx S, Camerlynck H, Somville J, Vercauteren M. Postsurgical compartment syndrome of the forearm diagnosed in a child receiving a continuous infra-clavicular peripheral nerve block. *Acta Anaesthesiol Belg* 2015;66(1):29-32.
5. Mannion S, Capdevila X. Acute compartment syndrome and the role of regional anaesthesia. *Int. Anesthesiol Clin* 2010;48(4):85-105.

6. Elliott KG, Johnstone AJ. Diagnosing acute compartment syndrome. *J Bone Joint Surg Br* 2003;85(5):625-32.
7. Harris C, Hobson M. The management of soft tissue injuries and compartment syndrome. *Surgery* 2015;33(6):251-6.
8. McQueen MM, Gaston P, Court-Brown CM. Acute compartment syndrome. Who is at risk? *J Bone Joint Surg Br* 2000;82(2):200-3.
9. Mossetti V, Ivani G. Controversial issues in pediatric regional anesthesia. *Pediatr Anaesth* 2012;22(1):109-14.
10. Blick SS, Brumback RJ, Poka A, Burgess AR, Ebraheim NA. Compartment syndrome in open tibial fractures. *J. Bone Joint Surg* 1986;68(9):1348-53.
11. Ferlic PW, Singer G, Kraus T, Eberl R. The acute compartment syndrome following fractures of the lower leg in children. *Injury* 2012;43(10):1743-6.
12. Park S, Ahn J, Gee AO, Kuntz AF, Esterhai JL. Compartment syndrome in tibial fractures. *J. Orthopaed. Trauma* 2009;23(7):514-8.
13. Tiwari A, Haq AI, Myint F, Hamilton G. Acute compartment syndromes. *Br. J. Surg* 2002;89(4):397-412.
14. Wall CJ, Lynch J, Harris IA, Richardson MD, Brand C, Lowe AJ, Suqrue M. Clinical practice guidelines for the management of acute limb compartment syndrome following trauma. *ANZ J. Surg* 2010;80(3):151-6.
15. Ojike NI, Roberts CS, Giannoudis P. Compartment syndrome of the thigh: a systematic review. *Injury* 2010;41(2):133-6.
16. Ozkayin N, Aktuglu K. Absolute compartment pressure versus differential pressure for the diagnosis of compartment syndrome in tibial fractures. *Int. Orthop* 2005;29(6):396-401.
17. Wright EM. Neurovascular impairment and compartment syndrome: a literature review. *Paediatr Nurs* 2009;21(3):26-9.
18. Kalyani BS, Fisher BE, Roberts CS, Giannoudis PV. Compartment syndrome of the forearm: a systematic review. *J. Hand Surg* 2011;36(3):535-43.
19. Ali P, Santy-Tomlinson J, Watson R. Assessment and diagnosis of acute limb compartment syndrome: A literature review. *International Journal of Orthopaedic and Trauma Nursing* 2014;18(4):180-90.
20. Panchamia JK, Orebaugh S. Acute Compartment Syndrome and Regional Anesthesiology – What Residents on the Acute Pain Management Service Should Know. *American Society of Regional Anesthesia and Pain Medicine* [serial on the Internet]. 2013 November. Available from: https://www.asra.com/content/documents/nov-13_asra_news.pdf
21. Olson SA, Glasgow RR. Acute compartment syndrome in lower extremity musculoskeletal trauma. *J Am Acad Orthop Surg* 2005;13(7):436-44.
22. Tiwari A, Haq AI, Myint F, Hamilton G. Acute compartment syndromes. *Br J Surg* 2002; 89(4):397-412.
23. Mar GJ, Barrington MJ, McGuirk BR. Acute compartment syndrome of the lower limb and the effect of postoperative analgesia on diagnosis. *British Journal of Anaesthesia* 2009;102(1):3-11.
24. Kosir R, Moore FA, Selby JH, Cocanour CS, Kozar RA, Gonzalez EA, Todd SR. Acute lower extremity compartment syndrome (ALECS) screening protocol in critically ill trauma patients. *J Trauma* 2007;63(2):268-75.
25. Ulmer T. The clinical diagnosis of compartment syndrome of the lower leg: are clinical findings predictive of the disorder? *J Orthop Trauma* 2002;16(8):572-7.
26. O'Sullivan MJ, Rice J, McGuinness AJ. Compartment syndrome without pain! *Ir Med J* 2002;95(1):22.
27. McQueen MM, Christie J, Court-Brown CM. Acute compartment syndrome in tibial diaphyseal fractures. *J Bone Joint Surg Br* 1996;78(1):95-8.
28. Shadgan B, Menon M, O'Brien PJ, Reid WD. Diagnostic techniques in acute compartment syndrome of the leg. *J. Orthop Trauma* 2008;22(8):581-7.
29. Tuckey J. Bilateral compartment syndrome complicating prolonged lithotomy position. *Br J Anaesth* 1996;77(4):546-9.
30. Staudt JM, Smeulders MJ, van der Horst CM. Normal compartment pressures of the lower leg in children. *J Bone Joint Surg Br* 2008;90(2):215-9.
31. Mubarak SJ, Owen CA, Hargens AR, Garetto LP, Akeson WH. Acute compartment syndromes: diagnosis and treatment with the aid of the wick catheter. *J Bone Joint Surg Am* 1978;60(8):1091-5.
32. Matsen FA 3rd, Veith RG. Compartmental syndromes in children. *J Pediatr Orthop* 1981;1(1):33-41.
33. McHale PM, LoVecchio F. Narcotic analgesia in the acute abdomen – a review of prospective trials. *Eur J Emerg Med* 2001;8(2):131-6.
34. Mubarak SJ, Pedowitz RA, Hargens AR. Compartment syndromes. *Curr Orthop* 1989; (3):36-40.
35. Whitesides TE, Haney TC, Morimoto K, Harada H. Tissue pressure measurements as a determinant for the need of fasciotomy. *Clin Orthop Relat Res* 1975;(113):43-51.
36. White TO, Howell GE, Will EM, Court-Brown CM, McQueen MM. Elevated intramuscular compartment pressures do not influence outcome after tibial fracture. *J Trauma* 2003;55(6):1133-8.
37. Garner AJ, Handa A. Screening tools in the diagnosis of acute compartment syndrome. *Angiology* 2010;61(5):475-81.
38. Aguirre JA, Gresch D, Popovici A, Bernhard J, Borgeat A. Case Scenario: Compartment Syndrome of the Forearm in Patient with an Infraclavicular Catheter. *Anesthesiology* 2013; 118(5):1198-205.
39. Hayakawa H, Aldington DJ, Moore RA. Acute traumatic compartment syndrome: A systematic review of results of fasciotomy. *Trauma* 2009;11(1):5-35.
40. Cascio BM, Pateder DB, Wilckens JH, Frassica FJ. Compartment syndrome: Time from diagnosis to fasciotomy. *J Surg Orthop Adv* 2005;14(3):117-21; discussion 120-1.
41. Dunwoody JM, Reichert CC, Brown KL. Compartment Syndrome Associated with Bupivacaine and Fentanyl Epidural Analgesia in Paediatric Orthopaedics. *J Paediatr Orthop* 1997;17(3):285-8.
42. Mubarak SJ, Wilton NC. Compartment syndromes and epidural analgesia. *J Paediatr Orthop* 1997;17(3):282-4.
43. Whitesides TE. Pain: friend or foe. *J Bone Joint Surg Am* 2001; 83-A(9):1424-5.
44. Tang WM, Chiu KY. Silent compartment syndrome complicating total knee arthroplasty: continuous epidural anesthesia masked the pain. *J Arthroplasty* 2000;15(2):241-3.
45. Somayaji HS, Hassan AN, Reddy K, Heatley FW. Bilateral gluteal compartment syndrome after total hip arthroplasty under epidural anesthesia. *J Arthroplasty* 2005 ;20(8):1081-3.
46. Kumar V, Saeed K, Panagopoulos A, Parker PJ. Gluteal compartment syndrome following joint arthroplasty under epidural anaesthesia: a report of 4 cases. *J Orthop Surg (Hong Kong)* 2007;15(1):113-7.
47. Maletis GB, Watson RC, Scott S. Compartment syndrome. A complication of intravenous regional anesthesia in the reduction of lower leg shaft fractures. *Orthopedics* 1989;12(6):841-6.
48. Driscoll EB, Maleki AH, Jahromi L, Hermez BN, Nelson LE, Vetter IL, Evenhuis S, Riesenberger LA. Regional anesthesia or patient-controlled analgesia and compartment syndrome in orthopedic surgical procedures: a systematic review. *Local Reg Anesth* 2016;6(9):65-81.
49. Richman JM, Liu SS, Courpas G, et al. Does continuous peripheral nerve block provide superior pain control to opioids? A meta-analysis. *Anesth Analg* 2006;102(1):248-57.
50. Harrington P, Bunola J, Jennings AJ, Bush DJ, Smith RM. Acute compartment syndrome masked by intravenous morphine from a patient-controlled analgesia pump. *Injury* 2000;31(5):387-9.
51. O'Sullivan ST, O'Donoghue J, McGuinness AJ, O'Shaughnessy M. Does patient-controlled analgesia lead to delayed diagnosis of lower limb compartment syndrome? *Plast Reconstr Surg* 1996;97(5):1087-8.
52. Richards H, Langston A, Kulkarni R, Downes EM. Does patient controlled analgesia delay the diagnosis of compartment syndrome following intramedullary nailing of the tibia? *Injury* 2004;35(3):296-8.
53. Cometa MA, Esch AT, Boezaart AP. Did continuous femoral and sciatic nerve block obscure the diagnosis or delay the treatment of acute lower leg compartment syndrome? A case report. *Pain Med* 2011;12(5):823-8.
54. Walker BJ, Noonan KJ, Bosenberg AT. Evolving compartment syndrome not masked by a continuous peripheral nerve block: Evidence-based case management. *Reg Anesth Pain Med* 2012;37(4):393-7.
55. Wu JJ, Lollo L, Grabinsky A. Regional anesthesia in trauma medicine. *Anesthesiol Res Pract* 2011; 2011: 713281. Published online 2011 Nov 21. doi: 10.1155/2011/713281
56. Soni S, Johannsson H. Does regional anaesthesia in trauma patients lead to delayed recognition of compartment syndrome? *Br J Hosp Med (Lond)* 2013;74(6):358.
57. Kucera TJ, Boezaart AP. Case Report Regional Anesthesia Does Not Consistently Block Ischemic Pain: Two Further Cases and a Review of the Literature. *Pain Medicine* 2014;15(2):316-9.

58. Uzel AP, Steinmann G. Thigh compartment syndrome after intra-medullary femoral nailing: possible femoral nerve block influence on diagnosis timing. *Orthop Traumatol Surg Res* 2009;95(4):309-13.
59. Rauf J, Iohom G, O'Donnell B. Acute compartment syndrome and regional anaesthesia – a case report. *Rom J Anaesth Int Care* 2015;22(1):51-54.
60. Munk-Andersen H, Laustrop TK. Compartment syndrome diagnosed in due time by breakthrough pain despite continuous peripheral nerve block. *Acta Anaesthesiol Scand* 2013;57(10):1328-30.
61. Ganeshan RM, Mamoowala N, Ward M, Sochart D. Acute compartment syndrome risk in fracture fixation with regional blocks. *BMJ Case Rep* 2015 Nov 26;2015. pii: bcr2015210499. doi: 10.1136/bcr-2015-210499.
62. Ananthanarayan C, Castro C, McKee N, Sakotic G. Compartment syndrome following intravenous regional anesthesia. *Can J Anaesth* 2000;47(11):1094-8.
63. Strecker WB, Wood MB, Bieber EJ. Compartment syndrome masked by epidural anesthesia for postoperative pain. Report of a case. *J Bone Joint Surg Am* 1986; 68(9):1447-8.
64. Pinheiro AA, Marques PM, Sá PM, Oliveira CF, da Silva BP, de Sousa CM. Compartment syndrome after total knee arthroplasty: regarding a clinical case. *Rev Bras Ortop.* 2015;50(4):478-81.
65. Ross O. Central neural blockade and compartment syndrome. *Anaesthesia* 1999;54:297.